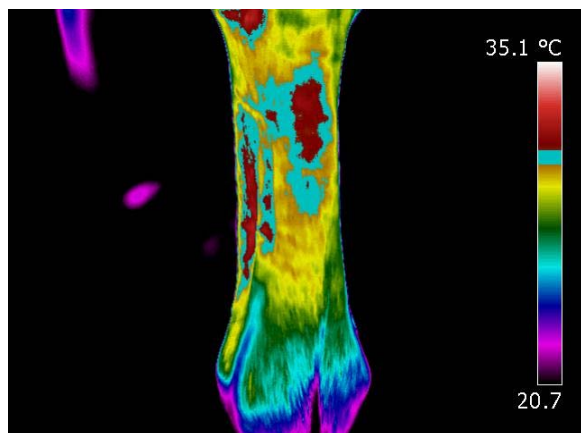


Equitherm Press Release 11.08.10

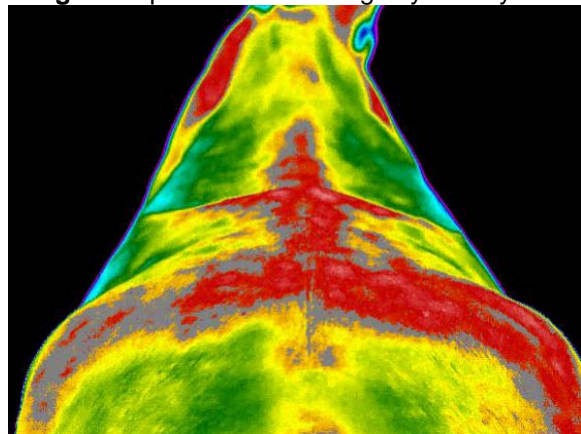
Examples of Equine Thermography Images

Image 1. Superficial tendon tear. Identified using Thermography before the horse was showing any clinical signs of lameness.



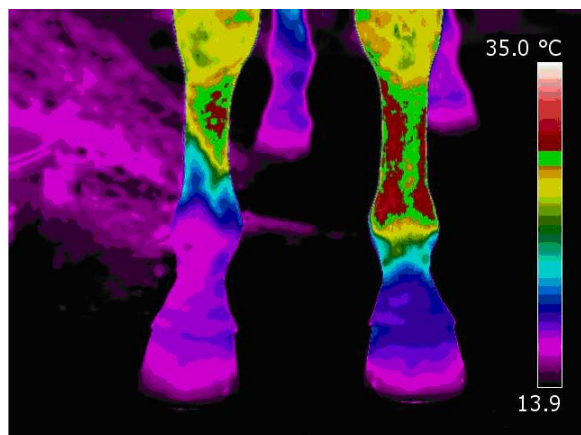
© Copyright Equitherm

Image 2. Equine back showing asymmetry in the hind quarters, a sign of muscle atrophy.



© Copyright Equitherm

Image 3. Eventer showing trauma on the nearside cannon post impact with a fence.



© Copyright Equitherm

For more information contact Sandie Chambers on +44 (0)1926 485221
Email: sandie.c@equitherm.com or visit: www.equitherm.com